

ISSN (E): 2708-2601

ISSN (P): 2708-2598

Medical Journal of South Punjab

Article DOI:10.61581/MJSP.VOL06/02/10

Volume 6, Issue 2, 2025

Print ISSN: 2708-2598
Online ISSN: 2708-2605



Evaluating the Preoperative Accuracy of Multislice CT in Determining Resectability of Periampullary Pancreatic Carcinoma

Publication History

Received: April 05, 2025 Revised: April 23, 2025

Accepted: June 10, 2025 Published: June 30, 2025

Authors and Affiliation:

Suhail Ahmed¹, Munazza Zaffar², Muhammad Irfan³,
Habibullah Maitlo⁴, Liaqat Ali⁵, Jawad Ali⁶

^{1,2,3,5} Pir Sayed Abdul Qadir Shah Jilani Institute of
Medical Sciences, Gambat, Pakistan

⁴ Sindh Institute of Child Health and Neonatology,
Sukkur, Pakistan

⁶ Khairpur Medical College, Khairpur, Pakistan

*Corresponding Author Email:

sundasiqbal1247@gmail.com

Copyright & Licensing:



Authors retain copyright and grant the journal right of first publication with the work simultaneously licensed under a [Creative Commons Attribution \(CC-BY\) 4.0 License](https://creativecommons.org/licenses/by/4.0/) that allows others to share the work with an acknowledgment of the work's authorship and initial publication in this journal.

Conflict of Interest:

Author(s) declared no conflict of interest.

Acknowledgment:

No Funding received.

Citation: Ahmed S, Zaffar M, Irfan M, Maitlo H, Ali L, Ali J. Evaluating the preoperative accuracy of multislice CT in determining resectability of periampullary pancreatic carcinoma. Medical Journal of South Punjab. 2025 September 30; 6(2):68-75.

Please scan me to access online.



An official publication of

Medteach Private Limited, Multan, Pakistan.

Email: farman@mjsp.com.pk, Website: <https://mjsp.com.pk/index.php/mjsp>



Evaluating the preoperative accuracy of multislice CT in determining resectability of periampullary pancreatic carcinoma

Suhail Ahmed¹, Munazza Zaffar², Muhammad Irfan³, Habibullah Maitlo⁴, Liaqat Ali⁵, Jawad Ali⁶
^{1,2,3,5} Pir Sayed Abdul Qadir Shah Jilani Institute of Medical Sciences, Gambat, Pakistan

⁴ Sindh Institute of Child Health and Neonatology, Sukkur, Pakistan

⁶ Khairpur Medical College, Khairpur, Pakistan

*Corresponding Author Email: sundasiqbal1247@gmail.com

ABSTRACT

Objective: To determine the preoperative diagnostic accuracy of Multislice CT in determining Resectability of Periampullary Pancreatic Carcinoma.

Methods: This cross-sectional validation study was conducted in the Radiology Department, Pir Abdul Qadir Shah Jeelani Institute of Medical Sciences Gambat, from January 2025 to April 2025. Patients with clinically suspected periampullary pancreatic carcinoma who underwent preoperative MDCT followed by surgical exploration were included. Resectability on MDCT was assessed based on tumor-vessel relationship, local invasion, and metastatic spread. Imaging findings were compared with intraoperative and histopathological results to calculate sensitivity, specificity, positive predictive value (PPV), negative predictive value (NPV), and overall accuracy.

Results: MDCT scan findings showed that 45 patients 76.3% had a clear tissue plane between the tumor and the superior mesenteric artery (SMA), and $<180^\circ$ SMV–PV involvement was seen in 64.4% patients. No evidence of metastasis was found in 74.6% patients. Other findings included abdominal ascites in 15.3%, SMA involvement in 22.0%, SMV–PV junction occlusion in 13.6%, liver metastasis in 11.9%, extra-pancreatic or peritoneal spread in 23.7%, and distant lymph node involvement in 22.0%.

Conclusion: Multislice CT provides a reliable non-invasive modality for preoperative assessment of periampullary pancreatic carcinoma resectability, particularly in ruling out unresectable disease.

Keywords: Periampullary pancreatic carcinoma, Multislice CT, Resectability, Preoperative assessment, Diagnostic accuracy

1. INTRODUCTION

Periampullary pancreatic carcinoma, a malignancy arising within 2 cm of the major duodenal papilla, represents a significant health burden worldwide¹. Globally, pancreatic cancer is the seventh leading cause of cancer-related deaths, with approximately 495,000 new cases and 466,000 deaths reported in 2020 alone². Among these, periampullary tumors account for 5–10%³ of pancreatic malignancies, with a slightly better prognosis than pancreatic head adenocarcinoma if diagnosed early. Despite advances in oncological treatment, late diagnosis remains common due to the tumor's anatomical location and nonspecific early symptoms, highlighting the urgent need for accurate preoperative staging to guide surgical management⁴.

Periampullary pancreatic carcinoma or tumors found in the surroundings of ampulla of Vater is a very daunting oncological problem as it usually comes late and also because of the complex structure of the area which makes surgery difficult to perform⁵. Tumor resectability is a vital determinant in the treatment planning since resection is the only chance of healing such patients. The aggressive character of periampullary tumors and early vascular invasion however predetermines the need to exactly study the tumor in preoperative staging so as to prevent unnecessary or non-therapeutic surgeries⁶.

Different diagnostic methods are available in the evaluation of periampullary tumor such as MRI/MRCP, EUS, and PET scans, which possess different abilities⁷. Although the modalities are quite comprehensive, their ubiquitous use is constrained by the problem of accessibility. With its high-quality imaging, multislice CT has become a landmark in the preoperative work-up of pancreatic cancer, providing a clear view of the tumor, and the relationship it has with other vascular structures as well as any evidence of any metastases⁸. The quality

of MDCT in determining the extent of a tumor and the vascularity directly affects the determination of the course of surgery and may change the fate of patients who are not fit to undergo a surgical procedure^{9,10}.

Although it is extensively used, the effectiveness of MDCT in differentiating resectable and unresectable periampullary pancreatic cancer is an issue of current research. The variability of the reported accuracy of MDCT requires additional research to streamline the imaging regimen as well as interpretation standards, which would improve preoperative planning and patient outcomes¹¹. This study will analyze the suitability of MDCT in the preoperative examination of periampullary pancreatic carcinoma in terms of its sensitivity, specificity, positive and negative predictive value as well as its overall accuracy in predicting the unresectability. Through this, it will help to add valuable knowledge on the optimization of preoperative diagnostic measures, help in choosing the right candidates to undergo surgery and could eventually enhance the outlook prognosis of this complicated condition in the patients.

2. METHODOLOGY

This cross-sectional validation study was conducted in the Radiology Department of Pir Abdul Qadir Shah Jeelani Institute of Medical Sciences, Gambat, from January 2025 to April 2025. A non-probability consecutive sampling technique was employed. Based on an expected sensitivity of 90%, specificity of 95%, disease prevalence of 30%, an expected range of $\pm 14\%$ (absolute precision), and a 95% confidence level, the calculated sample size for sensitivity was 59 and for specificity was 14¹². Therefore, a total sample size of 59 patients was selected for the study.

The study was initiated after receiving ethical consent of the institutional review board and College of Physicians and Surgeons Pakistan (CPSP).

Gastroenterologists or hepatobiliary surgeons referred to the Radiology Department patients with clinical suspicion of periampullary carcinoma (based on jaundice, weight loss, abdominal pain, or palpable mass) or radiological findings that suggested a periampullary mass (by ultrasound). All participants signed informed consent papers in writing after giving them an explanation of the aims of the study. The baseline data was taken such as age, gender, body mass index, ASA status and length of symptoms. The height and weight of every respondent were measured with the help of a stadiometer and digital scale respectively, to determine the BMI of any respondent.

They included patients aged 18 to 70 years of either sex, with a physical status of ASA I to III, and those with established tumors of the pancreatic head and the region surrounding the ampulla of Vater. Patients who had undergone surgical exploration of a possible periampullary mass as perioperative 3D-CT imaging and had been found to be medically fit to undergo surgical resection following anesthetic and cardiopulmonary assessment were eligibility criteria. Patients who had a history of major abdominal surgery that may alter the anatomy or have any impact on the MDCT imaging, extra-abdominal metastases (including brain metastasis), definitive hepatic metastases, ascites, superior mesenteric artery (SMA) or superior mesenteric vein (SMV-PV) confluence invasion were excluded. Patients whose pancreatic cancers were either in the body or tail of the pancreas were also eliminated.

All participants received a water-soluble oral contrast prior to imaging. A 100 mL dose of non-ionic iodinated contrast was administered intravenously, followed by a contrast-enhanced 64-slice multi-detector computed tomography (MDCT) scan of the abdomen. Enhanced images of the periampullary region were obtained and interpreted by two radiologists, who classified

each mass as resectable or non-resectable. Vascular involvement on MDCT was identified based on findings such as abrupt vessel caliber change, presence of collateral vessels, loss of vessel-tumor interface, or tumor invasion into the vessel. Within two weeks after imaging, patients underwent the appropriate surgical procedure as per clinical and disease criteria. Intraoperative findings were documented by the consulting surgeon, completing the data collection process. All findings were recorded using a structured data collection proforma.

The analysis of data was done with SPSS 26.0. Information on categorical variables (i.e. gender, ASA status, true positives (TP), true negatives (TN), false positives (FP), and false negatives (FN)) were reported as frequencies and percentages, whereas quantitative variables (i.e. age, height, weight, BMI, and duration of symptoms) were reported as mean \pm standard deviation. The sensitivity, specificity, positive predictive value (PPV), negative predictive value (NPV), and diagnostic accuracy of MDCT in establishing the resectability of periampullary carcinoma was calculated using a 2x 2 contingency table. The stratification was done based on age, BMI, ASA, gender, and duration of symptoms to determine the effect of these confounding factors. A p-value value below 0.05 was regarded to be significant.

3. RESULTS

The study included 59 patients with a mean age of 53.93 ± 8.74 years, of whom 7 (11.9%) were between 18–40 years and 52 (88.1%) between 41–70 years. There were 35 males (59.3%) and 24 females (40.7%). The mean weight, height, and BMI were 68.12 ± 8.95 kg, 167.76 ± 7.97 cm, and 24.39 ± 3.98 kg/m², respectively. Most patients were classified as ASA II (57.6%), followed by ASA III (30.5%) and ASA I (11.9%). The mean duration of symptoms was 2.97 ± 1.46

months, indicating relatively recent onset of disease among participants [Table-1].

MDCT scan findings showed that 45 patients (76.3%) had a clear tissue plane between the tumor and the superior mesenteric artery (SMA), and <180° SMV–PV involvement was seen in 38 (64.4%) patients. No evidence of metastasis was found in 44 (74.6%) patients. Other findings included abdominal ascites in 9 (15.3%), SMA involvement in 13 (22.0%), SMV–PV junction occlusion in 8 (13.6%), liver metastasis in 7 (11.9%), extra-pancreatic or peritoneal spread in 14 (23.7%), and distant lymph node involvement in 13 (22.0%) [Table-2].

Intraoperative findings revealed that complete tumor resection was achieved in 35 (59.3%) patients, while vascular involvement was observed in 17 (28.8%). Metastasis to the liver and peritoneum was noted in 5 (8.5%) patients each. Adjacent organ involvement occurred in 12 (20.3%) patients, and distant lymph node metastasis was found in 8 (13.6%), indicating variable disease spread at the time of surgery [Table No. 3].

A significant association was observed between intraoperative resectability status and radiologist evaluation findings ($\chi^2 = 6.35, p = 0.012$). The radiologic assessment demonstrated a sensitivity of 71.6%, specificity of 66.7%, positive predictive value (PPV) of 40.0%, negative predictive value (NPV) of 88.2%, and an overall diagnostic accuracy of 67.8%, suggesting moderate agreement between radiological and intraoperative findings [Table-4].

Table 1: Patient Demographics and baseline profile (n = 59)

Variable	Category	Presence
Age (years)	Mean±S.D	53.93±8.74
	18-40	7 (11.9)
	41-70	52 (88.1)
Gender	Male	35 (59.3)
	Female	24 (40.7)
Weight (kg)	Mean±S.D	68.12±8.95
Height (cm)	Mean±S.D	167.76±7.97
BMI (kg/m ²)	Mean±S.D	24.39±3.98
ASA Status	I	7 (11.9)
	II	34 (57.6)
	III	18 (30.5)
Duration of symptoms (months)	Mean±S.D	2.97±1.46

Table 2: Patient MDCT Scan Findings (n = 59)

Finding	Present n (%)	Absent n (%)
Clear tissue plane between tumor and SMA	45 (76.3)	14 (23.7)
<180° SMV–PV involvement	38 (64.4)	21 (35.6)
No evidence of metastasis	44 (74.6)	15 (25.4)
Abdominal ascites	9 (15.3)	50 (84.7)
SMA involvement	13 (22.0)	46 (78.0)
Occlusion of SMV–PV junction	8 (13.6)	51 (86.4)
Liver metastasis	7 (11.9)	52 (88.1)
Spread to extra-pancreatic organs/peritoneum	14 (23.7)	45 (76.3)
Distant lymph node involvement	13 (22.0)	46 (78.0)

Figure 1: Patient Radiologist Evaluation Findings (n = 59)

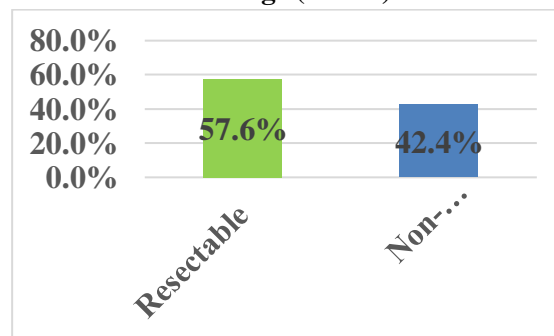


Table 3: Patient Intraoperative Surgical Findings (n = 59)

Finding	Present n (%)	Absent n (%)
Complete resection achieved	35 (59.3)	24 (40.7)
Vascular involvement	17 (28.8)	42 (71.2)
Metastasis to liver	5 (8.5)	54 (91.5)
Spread to peritoneum	5 (8.5)	54 (91.5)
Adjacent organ involvement	12 (20.3)	47 (79.7)
Distant lymph node involvement	8 (13.6)	51 (86.4)

Figure 2: Patient Intraoperative Resectability Status (n = 59)

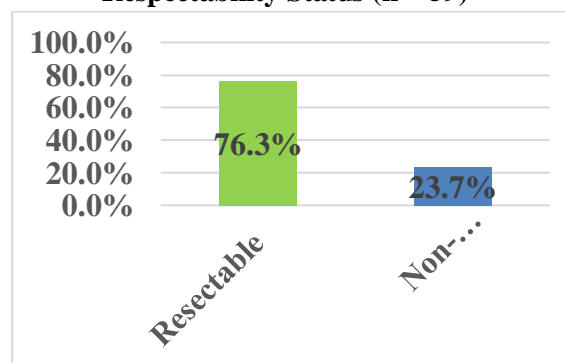


Table 4: Association of intraoperative respectability status and radiologist evaluation findings (n = 59)

Radiologist Evaluation Findings	Intraoperative Respectability Status		P
	Respectable	Non-Respectable	
Respectable	10	15	0.012
Non-Respectable	4	30	
Total	14	45	
Sensitivity=71.6%, specificity=66.7% , PPV=40.0%, NPV=88.2%, accuracy=67.8%			

4. DISCUSSION

In this study sensitivity of MDCT was found 71.6% with specificity, PPV and NPV 66.7%, 40% and 88.2%. Overall diagnostic accuracy was 67.8% in cases of intraoperative respectability in tumors of pancreas. These findings indicate that MDCT performed moderately well, particularly in ruling out unresectability, as reflected by the high NPV. When compared with previously published literature, this study outcomes fall within the lower middle range of reported values. Işcanlı et al¹³ reported a sensitivity and NPV of 100% with specificity of 72%, highlighting its strong utility in excluding unresectability.

Findings of this study have lower diagnostic performance compared to those reported in previous studies. Accuracy was close to 90% with multiphasic CT angiography in Zamboni et al¹⁴ Somers et al¹⁵ indicated the pooled sensitivity and specificity of 80-90, but the PPV was low because CT had low detection of micrometastases. Smith et al¹⁶ further pointed out the challenge of MDCT to detect early invasion of the vascular system as well as small peritoneal implants, which provided misleading verdicts.

Outcome-based studies have also assessed the effect of CT based assessment on clinical decision-making. According to Fagkrezos et al¹⁷, even in the case of high-resolution MDCT, 18% of surgical patients had unexpected unresectable disease during operations. Similar findings

were also made by Joo et al¹⁸ who reported that borderline cases were most problematic with a significant drop in the imaging accuracy between completely resectable and unresectable. Research by Tamm et al¹⁹ indicated that misclassification of CT in identifying vascular invasion resulted in unnecessary laparotomies in up to 20% of subjects and this highlights the shortcomings of preoperative imaging.

Likewise, Callery et al²⁰ reported that even with standardized CT criteria and radiologic scoring, up to one-third of patients labeled “resectable” on imaging later proved to have occult metastasis or unresectable vascular involvement. More recently, Klauss et al²¹ highlighted that despite advances in MDCT technology, 10–25% of patients still experience unexpected intraoperative upstaging, reinforcing the persistent performance gap of CT-based assessment.

In a study by House et al¹², 140 preoperative CT scans for periampullary tumors resulted in an 82% correct cancer diagnosis rate. Three-dimensional CT (3D-CT) accurately assessed local tumor spread and superior mesenteric vessel invasion in 93% and 95% of cases, respectively. For unresectable tumors, 3D-CT demonstrated 90% sensitivity, 95% specificity, and 94% overall accuracy, whereas for margin-positive resections, it showed reduced sensitivity (54%), specificity of 93%, positive predictive value (PPV) of 72%, negative predictive value (NPV) of 86%, and overall accuracy of 83%.

Hashemzadeh et al²² conducted a cross-sectional study on 32 patients with periampullary cancer undergoing MDCT prior to pancreaticoduodenectomy and found a resectability rate of 81.3%. MDCT achieved 100% sensitivity, 83.9% PPV, 100% NPV, and 84.4% overall accuracy, but specificity was only 16.7%. Faisal et al²³ analyzed 23 patients with periampullary tumors using

contrast-enhanced triphasic MDCT. Among these, 30.4% had ampullary masses, of which 85.7% were resectable, yielding an overall resectability rate of 85.7%. The study reported a PPV and accuracy of CT in assessing tumor resectability at 52.2%.

5. CONCLUSION

In this study, MDCT demonstrated moderate diagnostic performance in predicting the resectability of pancreatic tumors. It showed high reliability in ruling out unresectable disease (NPV 88.2%) but limited accuracy in positively predicting resectable tumors (PPV 40.0%).

6. REFERENCES

1. Aggour DI, Sallam AN, Abdelhamid MA, Abdehalim HA. Role of Multidetector CT in Preoperative Evaluation of Periampullary Neoplasms. *Egyptian Journal of Hospital Medicine*. 2024;94(1):630-6.
2. Lee DH, Lee SS, Lee JM, Choi JY, Lee CH, Ha HI et al. Pancreas CT assessment for pancreatic ductal adenocarcinoma resectability: effect of tube voltage and slice thickness on image quality and diagnostic performance. *Cancer Imaging*. 2023;23(1):126.
3. Issa M, Badawi M, Shalaby A, Noureldin K. Accuracy of Multislice Detector Computed Tomography in Staging Borderline Resectable Periampullary Pancreatic Carcinoma. *Ain Shams Journal of Surgery*. 2021;14(1):66-70.
4. Zhang C, Wang L, Zheng Z, Yao J, He L, Li J. Preoperative diagnosis of perineural invasion in patients with periampullary carcinoma by MSCT imaging: preliminary observations and clinical implications. *Abdominal Radiology*. 2023;48(2):601-7.
5. Tseng DS, Pranger BK, van Leeuwen MS, Pennings JP, Brosens LA, Mohammad NH, et al. The role of CT in assessment of extraregional lymph node involvement in pancreatic and periampullary cancer: a diagnostic accuracy study. *Radiology: Imaging Cancer*. 2021 19;3(2):e200014.
6. Yoen H, Kim JH, Hur BY, Ahn SJ, Jeon SK, Choi SY, et al. Prediction of tumor recurrence and poor survival of ampullary adenocarcinoma using preoperative clinical and CT findings. *European Radiology*. 2021 Apr;31(4):2433-43.
7. Park JH, Yoon YS, Lee S, Kim HY, Han HS, Lee JS, et al. Diagnostic accuracy of CT for evaluating circumferential resection margin status in resectable or borderline resectable pancreatic head cancer: A prospective study using axially sliced surgical pathologic correlation. *Korean Journal of Radiology*. 2022;23(3):322.
8. de Wilde AJ, de Jong EJ, Gurusamy KS, Abu Hilal M, Besselink MG, Dewulf MJ, et al. Diagnostic accuracy of cross-sectional and endoscopic imaging in ampullary tumours: systematic review. *British Journal of Surgery*. 2024;111(1):znad432.
9. Chen T, Zhang D, Chen S, Lu J, Guo Q, Cai S et al. Machine learning for differentiating between pancreatobiliary-type and intestinal-type periampullary carcinomas based on CT imaging and clinical findings. *Abdominal Radiology*. 2024;49(3):748-61.
10. Liu JY, Zhu L, Lin C, Han JS, Zhang C, Wang Y et al. Photon-counting CT for Pancreatic Cancer: Advancing Precision Imaging and Virtual Surgical Navigation. *Journal of Pancreatology*. 2025;31:10-97.
11. Ren S, Qin B, Daniels MJ, Zeng L, Tian Y, Wang ZQ. Developing and validating a computed tomography

- radiomics strategy to predict lymph node metastasis in pancreatic cancer. *World Journal of Radiology*. 2025 Aug 28;17(8):109373.
12. House MG, Yeo CJ, Cameron JL, Campbell KA, Schulick RD, Leach SD, et al. Predicting resectability of periampullary cancer with three-dimensional computed tomography. *J Gastrointest Surg*. 2004;8(3):280–8.
 13. Işcanlı E, Türkvatan A, Bostancı EB, Sakaoğulları Z. Assessment of surgical resectability of pancreatic adenocarcinomas with multidetector computed tomography: what are the possibilities and problems? *Turk J Gastroenterol*. 2014;25(4):416-23.
 14. Zamboni GA, Kruskal JB, Vollmer CM, Baptista J, Callery MP, Raptopoulos VD. Pancreatic adenocarcinoma: value of multidetector CT angiography in preoperative evaluation. *Radiology*. 2007;245(3):770-8.
 15. Somers I, Bipat S. Contrast-enhanced CT in determining resectability in patients with pancreatic carcinoma: a meta-analysis of the positive predictive values of CT. *Eur Radiol*. 2017;27(8):3408-3435.
 16. Smith SL, Rajan PS. Imaging of pancreatic adenocarcinoma with emphasis on multidetector CT. *Clin Radiol*. 2004 Jan;59(1):26-38.
 17. Fagkrezos D, Dervenis C, Triantopoulou C. value of multidetector computed tomographic angiography in marginally resectable pancreatic cancer. *Reports in Medical Imaging*. 2015 Jan 27:15-24.
 18. Joo I, Lee JM, Yoon JH. Imaging diagnosis of intrahepatic and perihilar cholangiocarcinoma: recent advances and challenges. *Radiology*. 2018;288(1):7-13.
 19. Tamm EP, Balachandran A, Bhosale PR, Katz MH, Fleming JB, Lee JH et al. Imaging of pancreatic adenocarcinoma: update on staging/resectability. *Radiol Clin North Am*. 2012;50(3):407-28.
 20. Callery MP, Chang KJ, Fishman EK, Talamonti MS, William Traverso L, Linehan DC. Pretreatment assessment of resectable and borderline resectable pancreatic cancer: expert consensus statement. *Ann Surg Oncol*. 2009;16(7):1727-33.
 21. Klauss M, Stiller W, Pahn G, Fritz F, Kieser M, Werner J, Kauczor HU, Grenacher L. Dual-energy perfusion-CT of pancreatic adenocarcinoma. *Eur J Radiol*. 2013;82(2):208-14.
 22. Hashemzadeh S, Mehrafsa B, Kakaei F, Javadrashid R, Golshan R, Seifar F et al. Diagnostic Accuracy of a 64-Slice Multi-Detector CT Scan in the Preoperative Evaluation of Periampullary Neoplasms. *J Clin Med*. 2018;7(5):91.
 23. Faisal M, Fathy H, Abu-Elela STB, Shams ME. Prediction of Resectability and Surgical Outcome of Periampullary Tumors. *Clin Surg*. 2018;3:1–5.